

Penicillium Marneffeii Infection in a Chinese Man with HIV Infection

Dr. K. K. Ho

Date:	12 July, 2000
Venue:	Yaumatei Skin Centre
Organizer:	Social Hygiene Service, DH; Clinico-pathological Seminar

CASE SUMMARY

History

A 34-year-old married Chinese salesman presented with fever, malaise and shortness of breath for one week before admission to United Christian Hospital in early February 2000. He was a hepatitis B carrier, and was fully treated for primary syphilis at YMT Male Social Hygiene clinic in the past. Two weeks after admission he developed an asymptomatic rash over his body.

Physical examination and investigations

On admission, he showed pallor, generalized lymphadenopathy and hepatosplenomegaly. There was no abnormality detected in his respiratory, cardiovascular or neurological system. Preliminary investigations showed pancytopenia with normal renal and liver function tests. Chest radiography did not show any abnormality.

The rash consisted of brownish papules over his upper limbs (Figure 1), which gradually spread to his face, oral mucosa (Figure 2), and lower limb. His torso was relatively spared. Some of the papules were easily eroded with crust formation, while some brownish papules showed central umbilication and some with collarette scale (Figure 3).

Trephine biopsy was performed which showed hypercellular marrow space and several ill-defined granuloma lesions composed of histiocytes. Yeast-like organisms were seen stuffed within the histiocytes as well as in the interstitial space. Grocott and PAS stain revealed the presence of single, centrally located transverse septum in some of the organisms. These

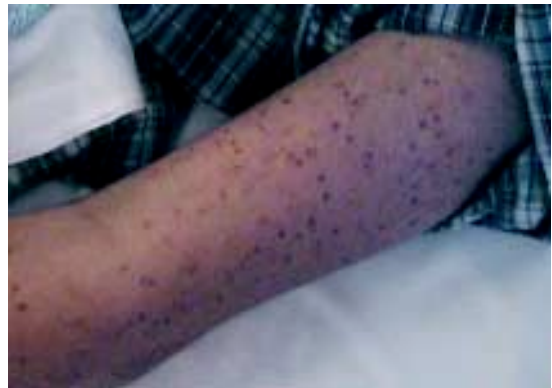

Figure 1: Asymptomatic brownish papules on upper limbs

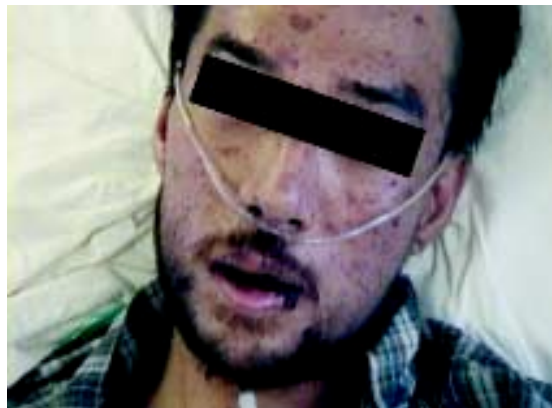

Figure 2: Facial and oral mucosal asymptomatic brownish papules

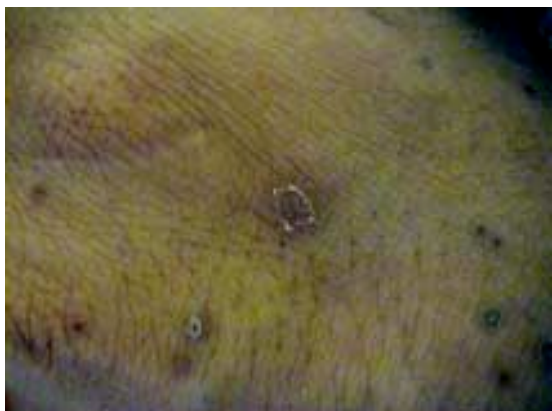


Figure 3: Close up of papules showing central umbilication and collarette scale

features were consistent with penicillium marneffeii species. ZN stain was performed, but did not reveal any acid-fast bacilli.

Skin biopsy showed large amount of fungal organisms in the epidermis and dermis. Little inflammatory cell was seen. Grocott stain of the organism showed morphology consistent with penicillium marneffeii (Figure 4).

Subsequently, blood culture grew penicillium marneffeii and HIV antibody was positive with CD4 count four cells per ul.

Diagnosis

A case of disseminated penicillium marneffeii infection with mucocutaneous involvement was diagnosed.

Differential diagnosis

This included infective causes (such as disseminated tuberculosis and deep fungal infection, such as histoplasmosis, cryptococcosis, coccidiomycosis and penicilliosis) and haematological malignancies with mucocutaneous involvement (such as non-Hodgkin lymphoma and acute leukaemia).

Treatment

He responded to parental amphotericin B followed by oral itraconazole. Recovery occurred with oral itraconazole, septrin and highly active anti-retroviral therapy.

REVIEW ON PENICILLIUM MARNEFFEII

Penicillium marneffeii was first isolated from the liver of a bamboo rat in Vietnam in 1956.¹ It is a dimorphic fungus, which is endemic in Southeast Asia, Thailand, southern China including Hong Kong.^{2,3} The first reported human infection with penicillium marneffeii was in a 61-year-old retired missionary with Hodgkin lymphoma who lived in Southeast Asia in 1973.⁴

Cases of disseminated penicillium marneffeii infection in HIV infected patients were first reported in 1988.⁵ By 1995, the number of reported disseminated Penicillium marneffeii infection in HIV infected patient rose up to over 1300 cases in Chiang Mai,⁶ the largest province in Northern Thailand, a period during which the number on AIDS cases in Thailand rose 13 fold.⁷

Suppararpinyo K. reported the largest case series of penicillium marneffeii with mucocutaneous involvement in 1994.⁸ He collected 80 culture confirmed Penicillium marneffeii infected patients. Most of them were HIV antibody positive from August 1987 to June 1992 at Chiang Mai University Hospital. The common presenting symptoms and signs were listed in Table 1.

Table 1. The common presenting symptoms and signs of penicillium marneffeii infected patients

Symptoms	Frequency
Fever	92%
Anaemia	77%
Weight loss	76%
Skin lesions	71%

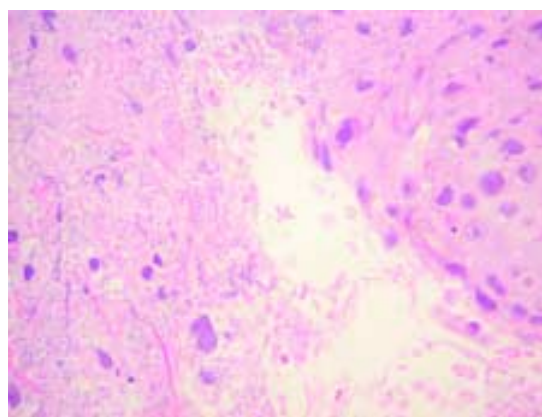
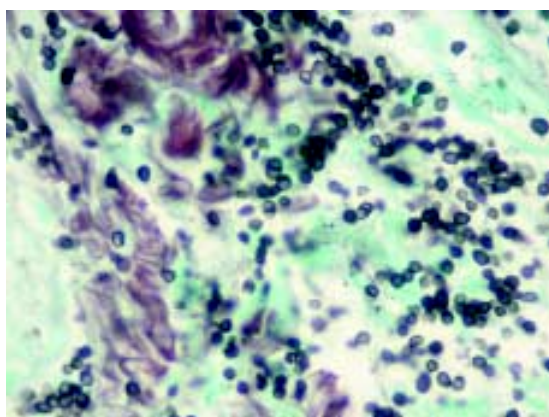


Figure 4: Skin biopsy shows fungal organisms of penicillium marneffeii: Grocott and H&E (By courtesy of Dr Y. H. Hui, Department of Pathology, UCH)

Mucocutaneous manifestation was the fourth commonest presenting symptoms (71%) in disseminated penicillium marneffeii infection. Central necrotic umbilication was the commonest presenting feature of mucocutaneous involvement followed by three cases of papules without umbilication and one case of erythematous maculopapular rash, subcutaneous nodule, acne-like lesion and folliculitis respectively. Penicillium marneffeii infection usually occurs late in the course of HIV infection with CD4 count consistently less than 50 cells per ul.⁸

The typical features of disseminated penicillium marneffeii with mucocutaneous involvement are dome-shaped papules with central umbilication or partial necrosis predominantly over the face and upper limb. Oral mucosa involvement is very common.

The local situation could be reflected from the first and second 100 AIDS cases in Hong Kong. In comparing the first and second 100 AIDS cases, it was found that penicillium marneffeii was the third common AIDS defining illness and the trend was increasing from 5% to 14%.⁹

It was easy to culture penicillium marneffeii from various specimens with 100% sensitivity in bone marrow culture followed by 90% in skin biopsy and 76% in blood culture.⁹

Histopathologically, histoplasma capsulatum may resemble penicillium marneffeii when found intracellularly. But when found extracellularly, penicillium marneffeii are elongated¹⁰ (8-13 um) and generally much larger than those of histoplasma capsulatum¹¹ (2-5 um). Penicillium marneffeii reproduces by fission with a centrally located transverse septum while histoplasma capsulatum is divided by budding.

Galactomannan test, using monoclonal antibody can detect a specific galactomannan having at least one epitope common to penicillium marneffeii and aspergillus¹² but not histoplasma. Its titre can be use to diagnose, monitor and differentiate penicillium marneffeii from other infection especially histoplasmosis. The mortality rate of patients with disseminated penicillium marneffeii infection was very high if treatment was delayed, regardless of whether the patient is concurrently infected with HIV or not.

The fungus was sensitive to amphotericin B, itraconazole and ketoconazole. The current recommended treatment regimen for HIV infected

patients with disseminated penicillium marneffeii infection is intravenous amphotericin B 0.6 mg/kg/day for two weeks, followed by oral itraconazole 400 mg per day in two divided doses for the next 10 weeks.¹³ It was found that 57% relapsed within one year¹⁴ in HIV infected patients if no secondary prophylaxis (itraconazole 200 mg daily) was given.

Learning points:

Disseminated opportunistic fungal infection like penicillium marneffeii may be the presenting feature of AIDS in this locality. It is potentially lethal, but treatable if diagnosed earlier.

References

1. Capponi M, Sureau P, Segretain G. Penicilliosis de Rhizomys sinensis. Bull Soc Pathol Exot 1956;49:418-21.
2. Deng Z, Ribas JL, Gibson DW, et al. Infection caused by P marneffeii in China and Southeast Asia: review of eighteen published cases and report of four more Chinese cases. Rev Infect Dis 1988;10:640-52.
3. Jayanetra P, Nitiyanant P, Ajello L, et al. Penicilliosis marneffeii in Thailand: report of five human cases. Am J Trop Med Hyg 1984;33:637-44.
4. DiSalvo AF, Ficking AM, Ajello L. Infection caused by Penicillium marneffeii: description of first natural infection in man. Am J Clin Pathol 1973;60:259-63.
5. Piehl MR, Kaplan RL, Haber MH. Disseminated penicilliosis in a patient with acquired immunodeficiency syndrome. Arch Pathol Lab Med 1988;112:1262-4.
6. Phillips P. Penicillium marneffeii part of Southeast Asian AIDS. JAMA 1996;276:86-7.
7. Brown T, Sittitrai W, Vanichseni S, et al. The recent epidemiology of HIV and AIDS in Thailand. AIDS 1994;8: S131-41.
8. Supparatpinyo K, Khamwan C, Baosoung V, et al. Disseminated Penicillium marneffeii infection in Southeast Asia. Lancet 1994; 344:110-3.
9. Wong KH, Lee SS. Comparing the first and second hundred AIDS cases in Hong Kong. Singapore Med J 1998;39:236-40.
10. Cooper CR, McGinnis MR. Pathology of Penicillium marneffeii: an emerging acquired immunodeficiency syndrome-related pathogen. Arch Pathol Lab Med 1997;121:798-804.
11. Deng Z, Connor DH. Progressive disseminated penicilliosis caused by Penicillium of the causative organism from Histoplasma capsulatum. Am J Clin Pathol 1985;84:323-7.
12. Arrese Estrada J, Stynen D, Van Custsem J, et al. Immunohistochemical identification of Penicillium marneffeii by monoclonal antibody. Int J Dermatol 1992;31:410-2.
13. Sirisanthana T, Supparatpinyo K, Perriens J, et al. Amphotericin B and itraconazole for treatment of disseminated Penicillium marneffeii infection in human immunodeficiency virus-infected patients. Clin Infect Dis 1998;26:1107-10.
14. Supparatpinyo K, Perriens J, Kenrad E, et al. A controlled trial of itraconazole to prevent relapse of Penicillium marneffeii infection in patients infected with the human immunodeficiency virus. New Eng J Med 1998;24:1739-43.