

Dermato-venereological Quiz

KHN Chan 陳厚毅, WYM Tang 鄧旭明, KF Lok 駱勁鋒, WY Lam 林永賢

A 49-year-old man presented with painful and itchy erythematous rash over bilateral lower limbs for 3 months. There was no provoking factor and he did not take any new medication recently. The rash worsened during the period. He had known history of pulmonary tuberculosis and haemorrhoidectomy. Physical examination showed erythematous macular lesion over bilateral lower limbs and ulceration over left posterior calf. Subcutaneous nodules were found over the lower limbs but no there was no palpable lymph node (Figures 1 & 2).

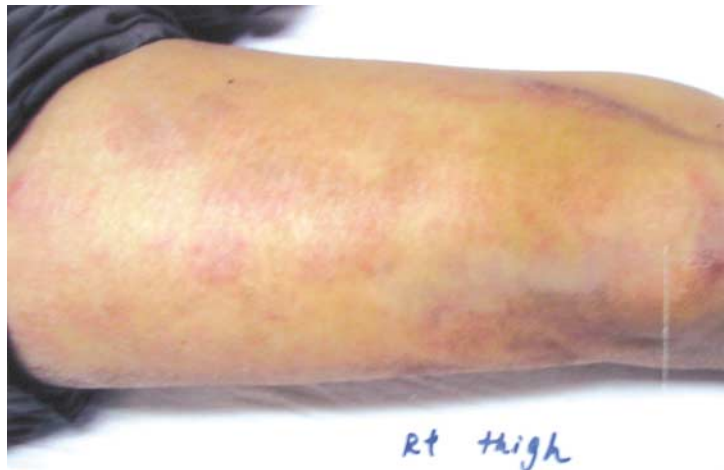

Figure 1.

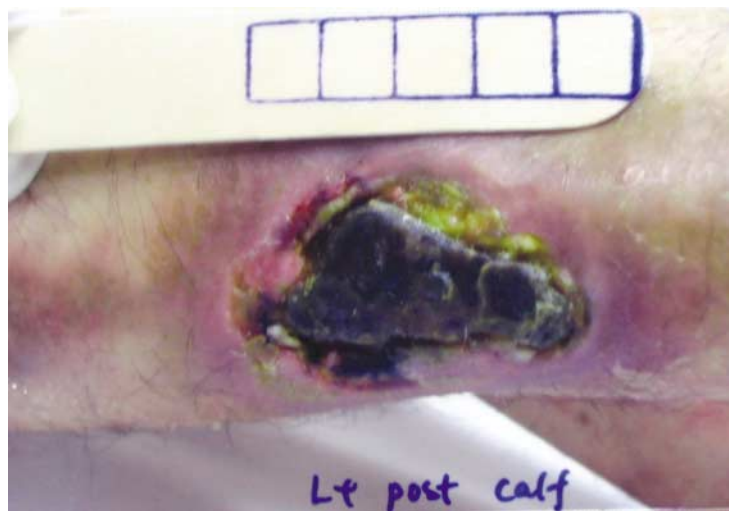

Figure 2.

Social Hygiene Service, Department of Health, Hong Kong

KHN Chan, MBBS(HK), MRCP(UK)
WYM Tang, FRCP(Edin), FHKAM(Medicine)

Department of Clinical Pathology, Tuen Mun Hospital, Hong Kong

KF Lok, MBChB(CUHK)
WY Lam, FHKAM(Pathology)

Correspondence to: Dr. KHN Chan

Cheung Sha Wan Dermatology Clinic, 3/F West Kowloon Health Centre, 303 Cheung Sha Wan Road, Kowloon, Hong Kong

Questions

1. What are the clinical differential diagnoses?
2. Diagnostic skin biopsy was performed. The histology was shown. What is the diagnosis? (Figures 3 & 4)
3. Immunohistochemistry was performed which showed CD 3 and CD 56 +ve. T cell receptor beta gene rearrangement was +ve. EBV EBEB mRNA was demonstrated in the cells in in-situ hybridization. What is the diagnosis?
4. What are the other important investigations?
5. What is the outcome of the disease?

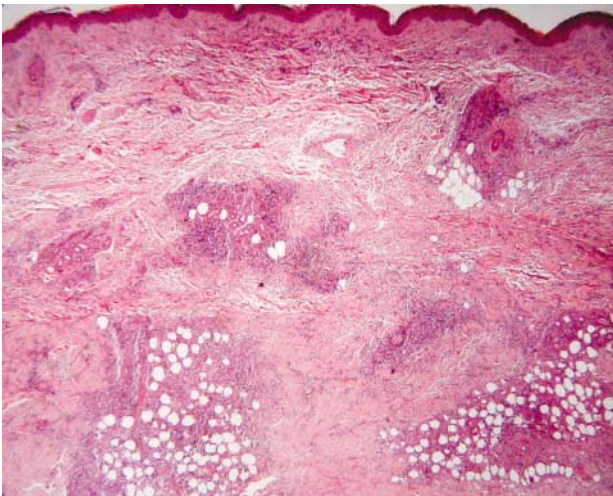


Figure 3. H & E stain 20X

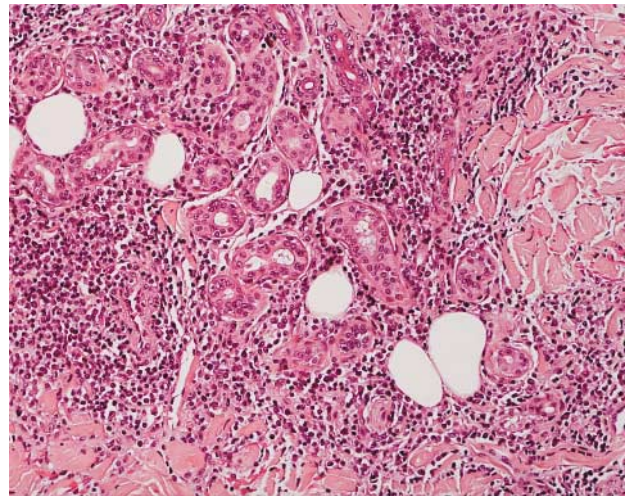


Figure 4. H & E stain 100X