

## Dermato-venereological Quiz

CK Kwan 關志強

A 57-year-old Chinese lady presented with progressive swelling of both lips for one year. The lower lip was more severely affected and there was no overlying ulcer, scaling or fissure. The patient did not have habits of using lipstick or taking herbal medication. She was a non-smoker and non-drinker. She had hypertension, hyper-lipidaemia and diabetes mellitus on long term medication with no alteration in treatment regimen in recent few years. Besides the lip swelling, the patient did not have any gastrointestinal upset or other systemic symptoms. Physical examination revealed that both lips were uniformly swollen (Figures 1 & 2) with no significant surface changes. The patient had multiple dental caries.

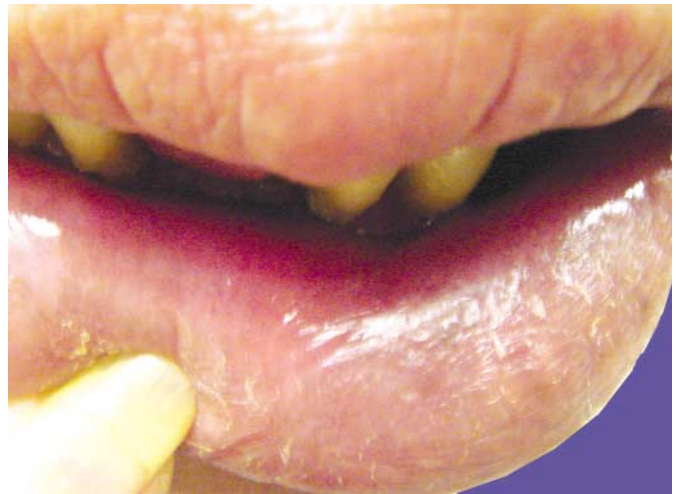

Figure 1.

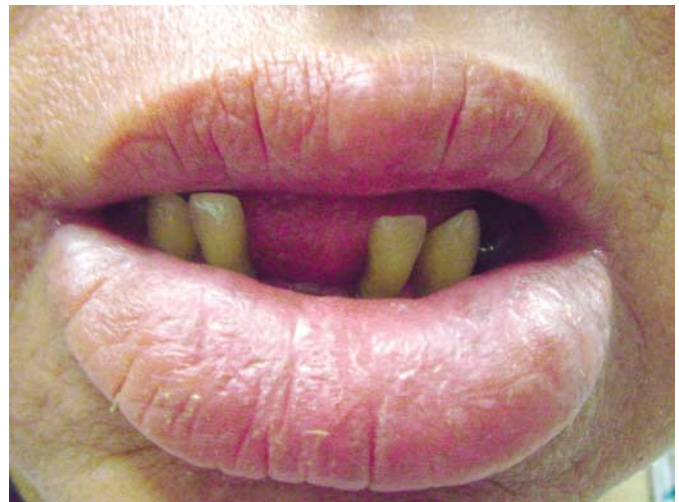

Figure 2.

### Questions

1. What are the likely differential diagnoses?
2. Punch skin biopsy on lower lip was performed and histopathological examination (Figures 3 & 4) revealed focal spongiosis and exocytosis, mild acanthosis and elongation of the rete ridges. The dermis showed granulomatous inflammation with epithelioid cells,

Social Hygiene Service, Department of Health, Hong Kong

CK Kwan, MBBS(HK), MRCP(UK)

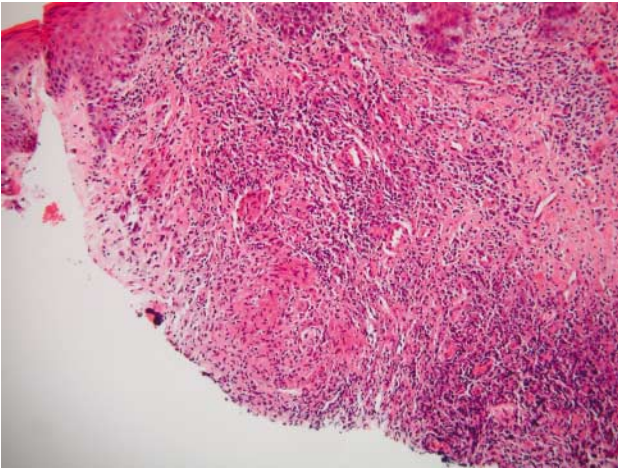
Correspondence to: Dr. CK Kwan

Cheung Sha Wan Dermatology Clinic, 3/F, West Kowloon Health Centre, 303 Cheung Sha Wan Road, Kowloon, Hong Kong

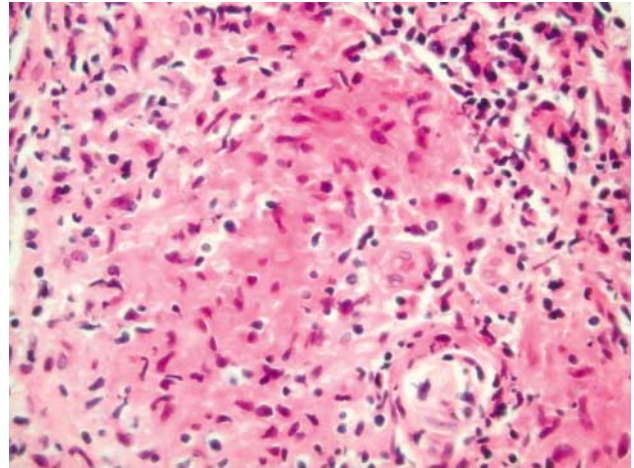
multinucleated giant cells, chronic inflammatory cell infiltrate and dilated vessels. There was no evidence of amyloidosis. Fungal stains and Ziehl-Neelsen stain were negative. What is your diagnosis for this patient? What disorder should you consider in cases with such histological

findings.

3. What other associated features should be looked for?
4. What aggravating factor should be considered?
5. What are the treatments?



**Figure 3.** H & E stain, Original magnification x 100.



**Figure 4.** H & E stain, Original magnification x 400.

## Answers to Dermato-venereological Quiz on pages 150-151

1. Differential diagnoses for this lady include contact dermatitis, angio-oedema, chronic infection especially secondary to odontogenic infection, sarcoidosis, oral Crohn's disease, cheilitis granulomatosa, cheilitis grandularis and Ascher syndrome.
2. The diagnosis for this patient is cheilitis granulomatosa. Cheilitis granulomatosa can be found in Melkersson-Rosenthal syndrome (MRS) and oral Crohn's disease.
3. The patient should be examined for any facial nerve palsy and lingua plicata. Cheilitis granulomatosa with, facial palsy and lingua plicata form the triad of Melkersson-Rosenthal syndrome (MRS). MRS is a rare disorder with no sex, racial or ethnic predilection with unknown aetiology. However, the triad may not occur simultaneously and monosymptomatic or oligosymptomatic form is often encountered in which orofacial swelling is the most important and consistent presentation. The facial nerve palsy is indistinguishable from Bell's palsy. It may develop months or even years after orofacial swelling. It is usually unilateral but both sides can be affected. Gastrointestinal symptoms particularly abdominal pain and per rectal bleeding should be looked for as oral Crohn's disease is another important differential diagnosis.
4. Odontogenic infection can be provocation factor for cheilitis granulomatosa. Such infectious foci should be actively sought and treated.
5. Emollient, cold compression and antihistamine can be used for symptomatic relief. Intralesional steroid therapy may be helpful in some patients. Other agents reported to have limited success include minocycline, clofazimine, nonsteroidal anti-inflammatory agents, methotrexate and tacrolimus. Chronic disfiguring cases may require reduction cheiloplasty.

## Corrigendum

On page 81 of the case report "POEMS syndrome with glomeruloid haemangioma: a case report" published in the Summer 2007, the following errors need correction:

The name for the author of WY Lam should be WL Lam (林蔚龍) and from Princess Margaret Hospital.