

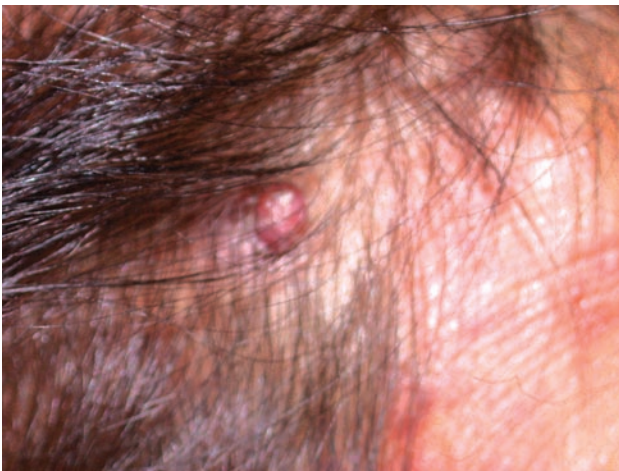## Dermato-venereological Quiz

WY Leung 梁偉耀

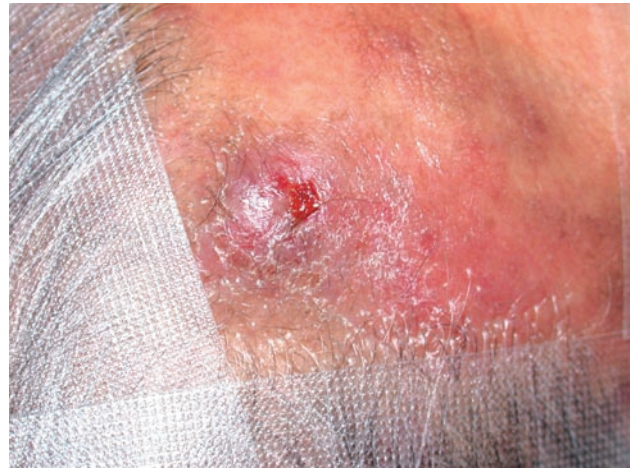
---

This 78-year-old Chinese lady presented with a rapidly enlarging violaceous nodule over scalp for three months. There was all along no bleeding or erosion over the nodule. The lesion was asymptomatic and there was no lymphadenopathy.

She has diabetes mellitus, ischemic heart disease and hypertension and was on warfarin. Examination revealed a 1.5 cm violaceous nodule over her scalp (Figures 1 & 2). Skin biopsy was performed. Histologically, there was delicate primitive vascular channels and a few individual polygonal cells showing moderate cytoplasmic staining (Figures 3 & 4).



**Figure 1.** A violaceous nodule on scalp.



**Figure 2.** Closer look of the violaceous nodule.

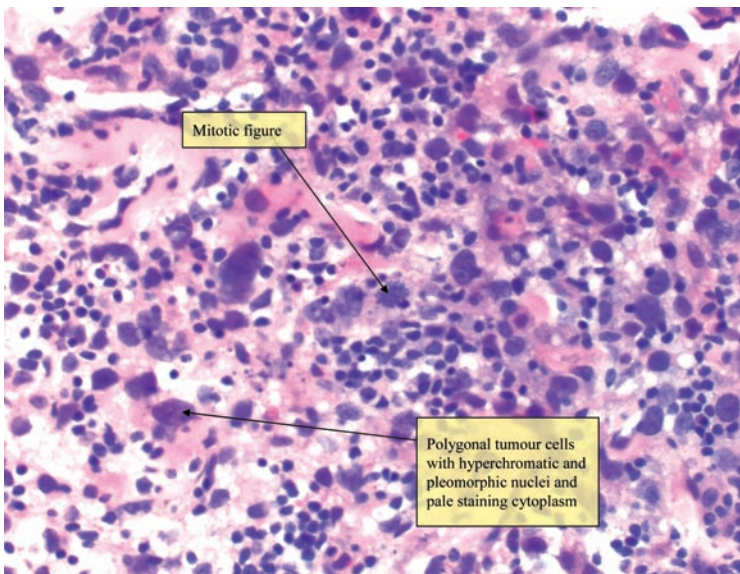
---

**Socail Hygiene Service, CHP, Department of Health, Hong Kong**

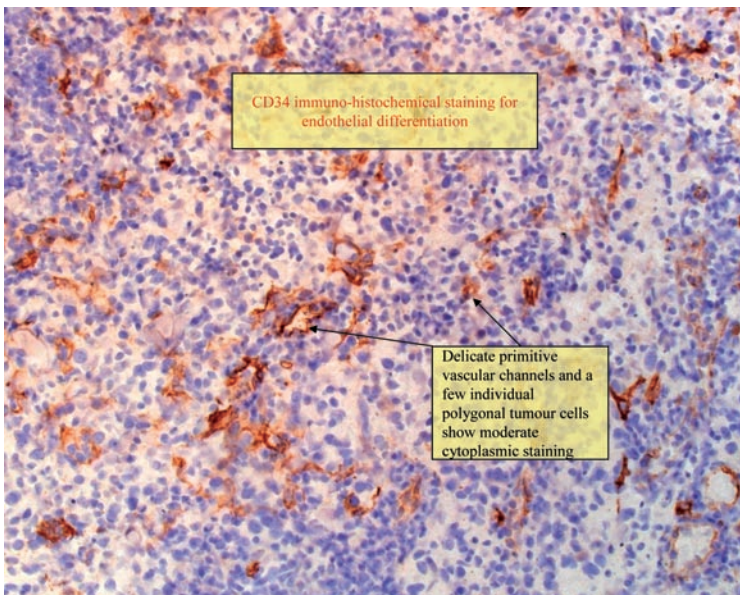
WY Leung, MBChB(CUHK), MRCP(UK), FHKCP, FHKAM(Medicine)

Correspondence to: Dr. WY Leung

Yaumatei Dermatology Clinic, 12/F Yaumatei Specialist Clinic (New Extension), 143 Battery Street, Yaumatei, Kowloon, Hong Kong



**Figure 3.** Pathology finding. (H&E, Original magnification x 400)



**Figure 4.** CD 34 immuno-histochemical staining. (Original magnification x 200)

## Questions

1. What are the likely differential diagnoses?
2. What are the most likely clinical diagnosis and associations?
3. What is the natural history of this condition?
4. What is the treatment?

### **Answers to Dermato-venereological Quiz on pages xx-xx**

1. Differential diagnoses for this lady include angiolymphoid hyperplasia with eosinophilia, pyogenic granuloma, haemangioma, lymphoma, angiosarcoma, metastases, Kaposi's sarcoma, granuloma faciale and deep fungal infection.
2. The clinical diagnosis is angiosarcoma. Angiosarcoma is an uncommon, malignant tumour originating from vascular endothelial cells. It accounts for less than 1% of skin malignancies of the head and neck and usually presents on the scalp of elderly patients. It is associated with post mastectomy lymphoedema and previous history of irradiation.
3. Angiosarcoma is an aggressive tumour and the prognosis is poor. Only a minority of patients survived 5 years or longer and most patients died within 15 months of presentation.
4. Wide local excision combined with radiotherapy is the main treatment of choice. However, the tumour is usually too advanced for surgery by the time of presentation. Palliative chemotherapy may play a role for un-resectable and disseminated tumour.